

INTRAOPERATIVE LOCALIZATION IN NEUROSURGERY

Presented by : DR. SHAILESH JAIN

INDEX

- ❖ HISTORY
- ❖ ANATOMY
- ❖ INTRA OP. ULTRASOUND
- ❖ STEREOTACTIC LOCALIZATION:-
 - 1) FRAME BASED
 - 2) FRAMELESS
- ❖ INTRAOP. MRI
- ❖ INTRAOP. MOBILE CT SCAN
- ❖ INTRAOP. ELECTROPHYSIOLOGY
- ❖ INTRAOPERATIVE BRAINSTEM NUCLEI LOCALIZATION / MAPPING

HISTORY

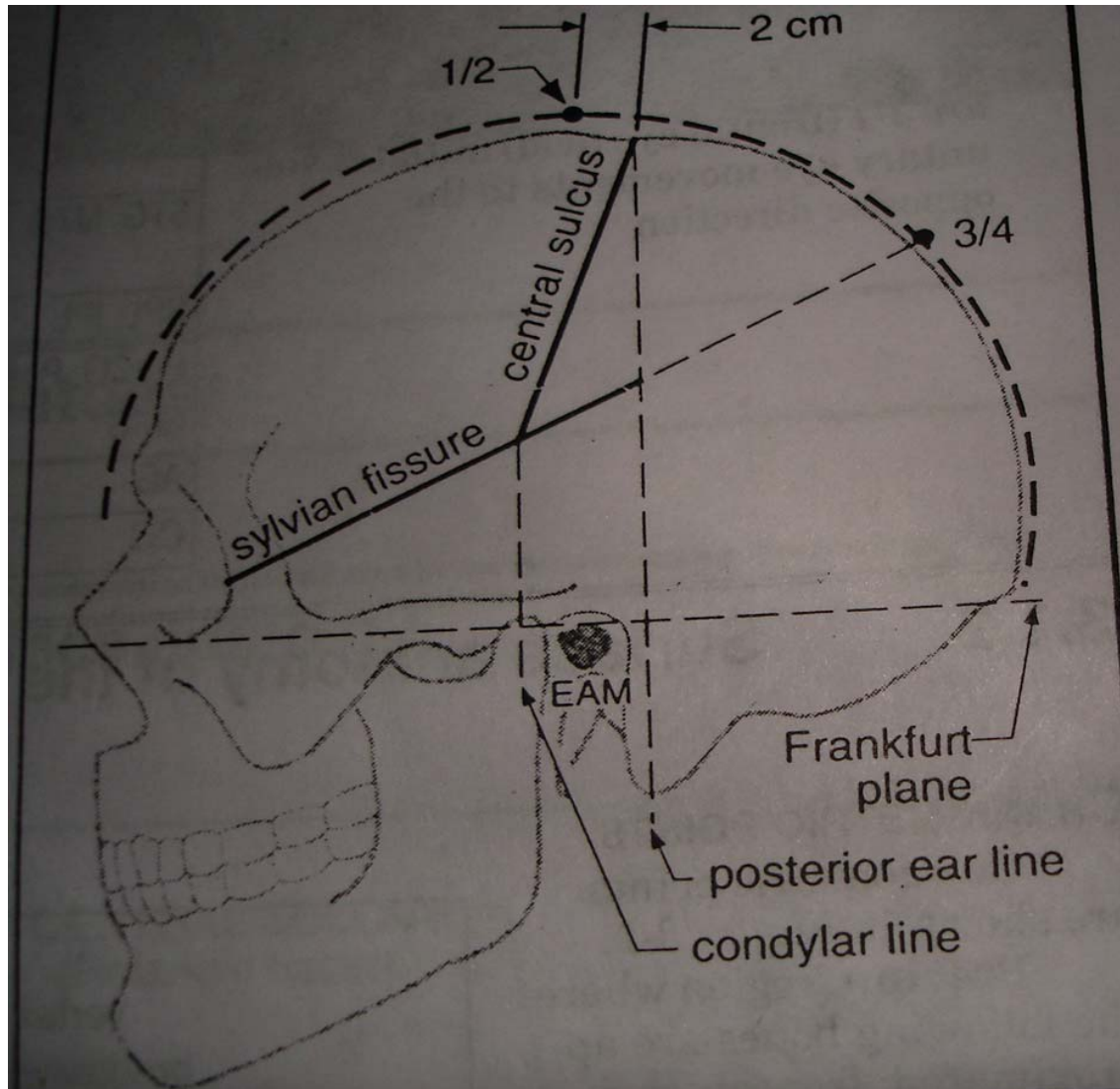
- ❖ **BOUILLAUD(1796- 1875):-** Brain role in movement & intelligence; speech localization is in the anterior lobes.
- ❖ **GRUNBAUM & SHERRINGTON:-**
Established separation of the motor area in the prerolandic zone & the sensory area in the postrolandic zone in higher primates.
- ❖ **HARVEY CUSHING:-** Map the human cerebral cortex with faradic electrical stimulation in the conscious patient.
- ❖ **PENFIELD & RASMUSSEN:-** Outlined the motor & sensory Homunculus.
- ❖ **BRODMANN(1909):-** Identified 52 cortical areas, grouped in to 11 Histologic regions, on cortical maps.

DIFFERENT WAYS TO LOCALISE

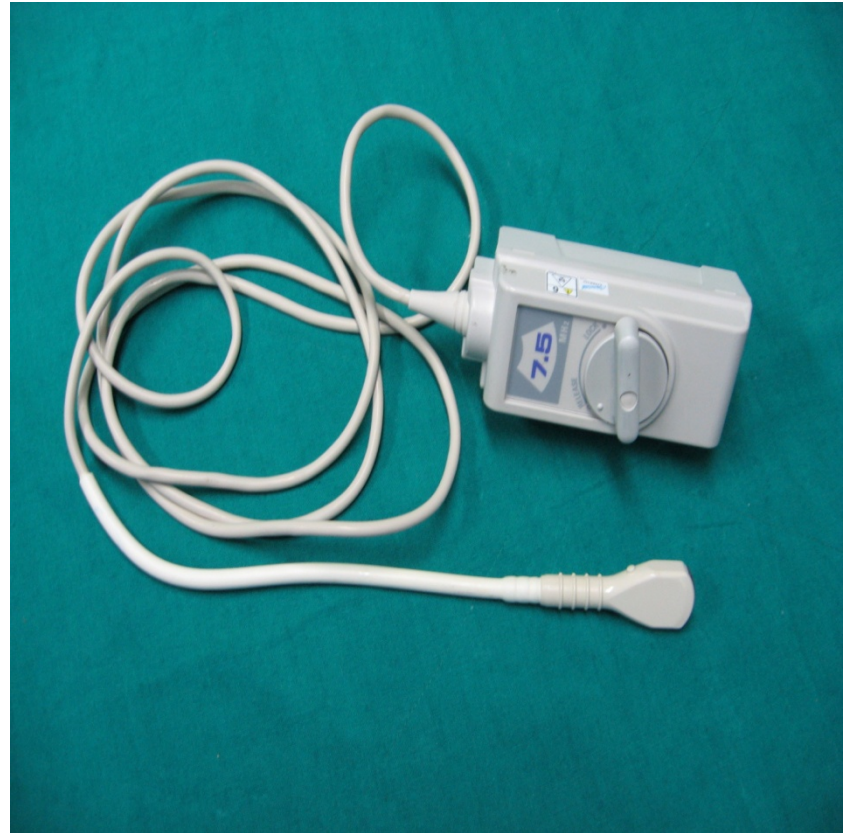ANATOMICALLY:

- ❖ **TAYLOR HAUGHTON LINES:-** can be constructed on an angiogram, CT scout film, or x-ray skull, & can then be reconstructed on the patient in the O.T. based on visible external landmarks.
- ❖ Motor strip lies anywhere from 4 to 5.4cm behind the coronal suture.
- ❖ **MRI:-** Knob appearance of Precentral gyrus with “**INVERTED OMEGA / EPSILON SIGN**” of Central sulcus or Rolandic fissure.
- ❖ **CENTRAL SULCUS:** S- shaped appearance on left side & Inverted S- shaped on right side.

TAYLOR HAUGHTON LINES



INTRAOPERATIVE ULTRASOUND (IOUS)



INTRAOPERATIVE **ULTRASOUND (IOUS)**

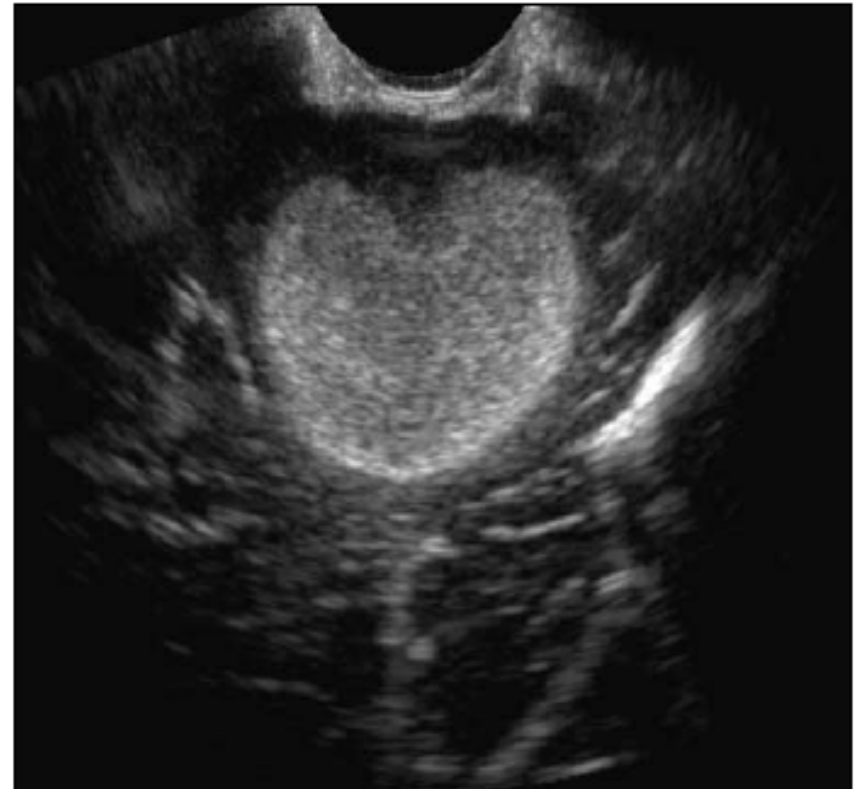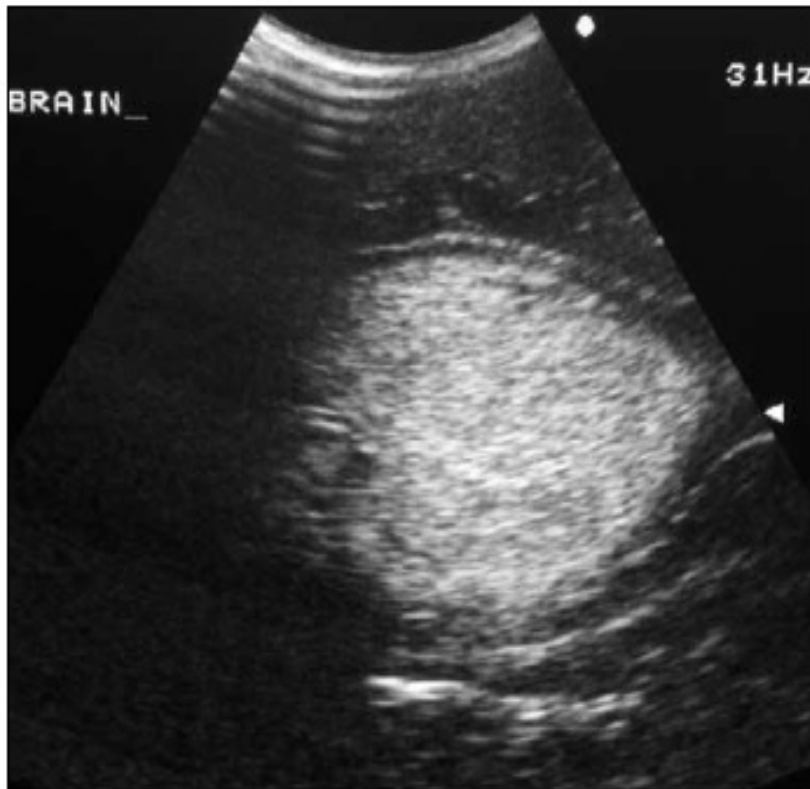
- Wild & Reid in 1978, 1st described the use of USG in neurosurgery.
- Sonography is truly real time (>18 frames per second).
- A rapid and effective way to localize and characterize diseases of the brain.
- **Frequency** : higher freq. (E.G. 10MHz) yields a higher resolution but with high degree of absorption so, less penetration.

INTRAOPERATIVE **ULTRASOUND**

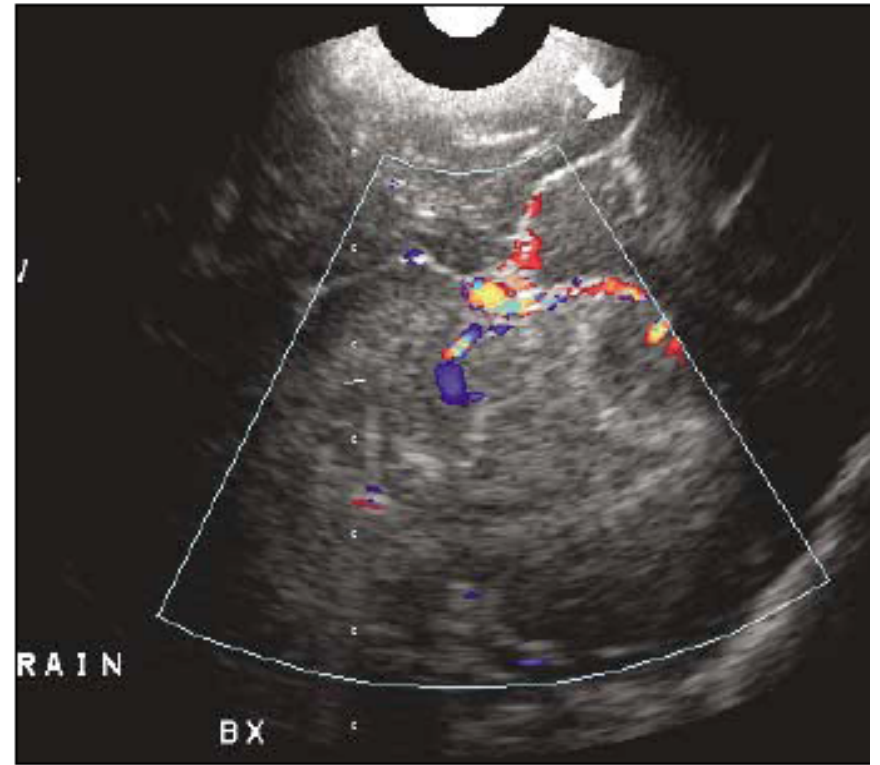
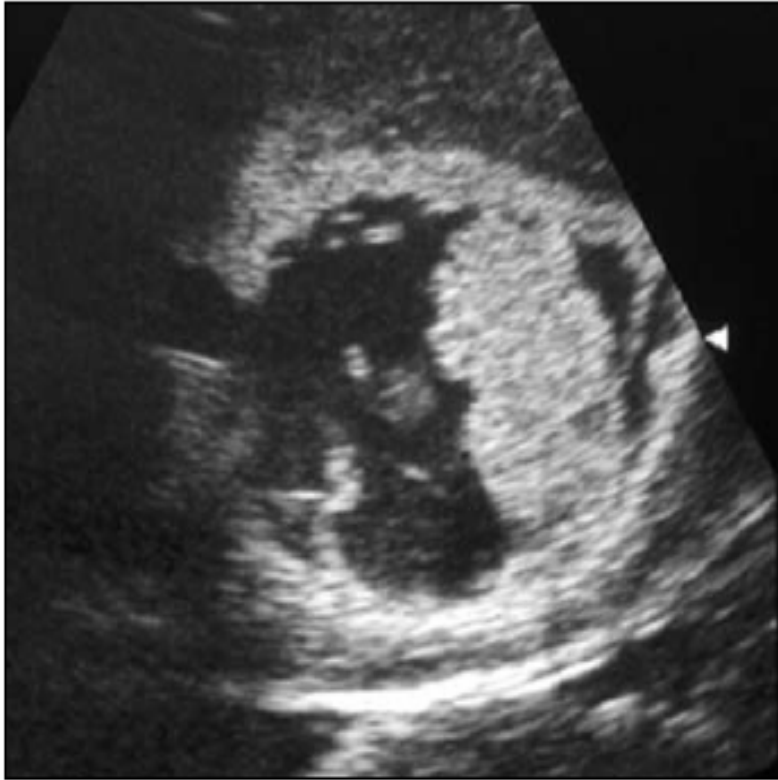
Normal Brain

- In the normal brain, surface sulci appear echogenic, whereas the underlying parenchyma is homogeneously hypoechoic.
- Orientation gained by determining the position of the Ventricles & Interhemispheric fissure.

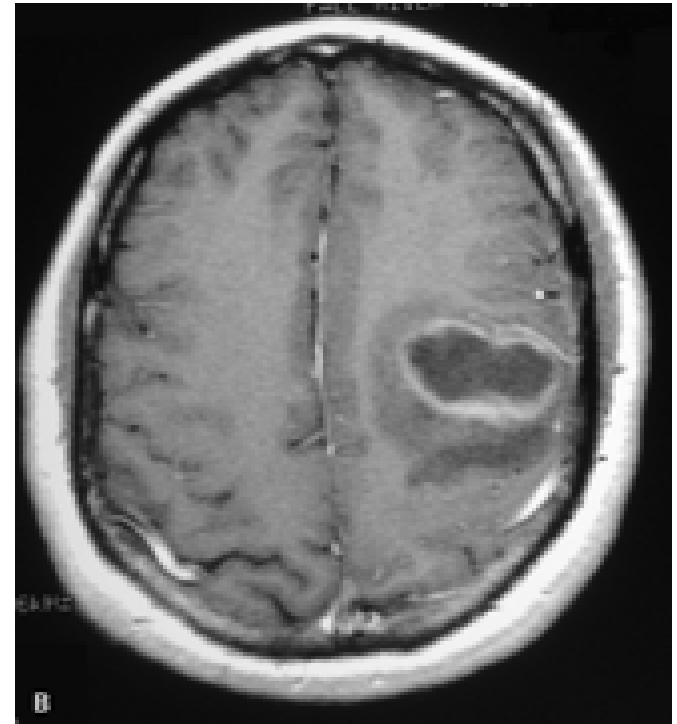
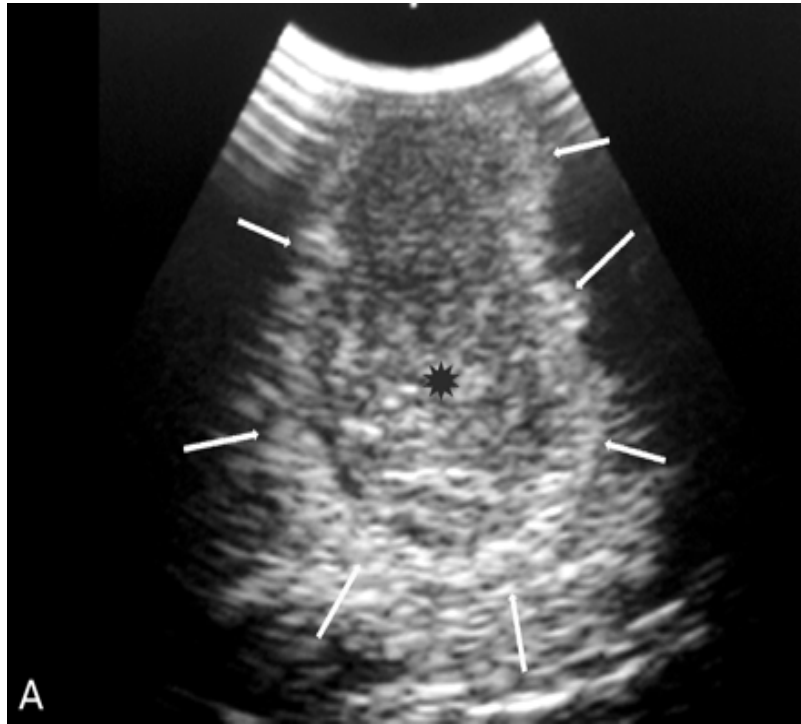
INTRAOPERATIVE ULTRASOUND



INTRAOPERATIVE ULTRASOUND



INTRAOPERATIVE **ULTRASOUND**



INTRAOPERATIVE **ULTRASOUND**

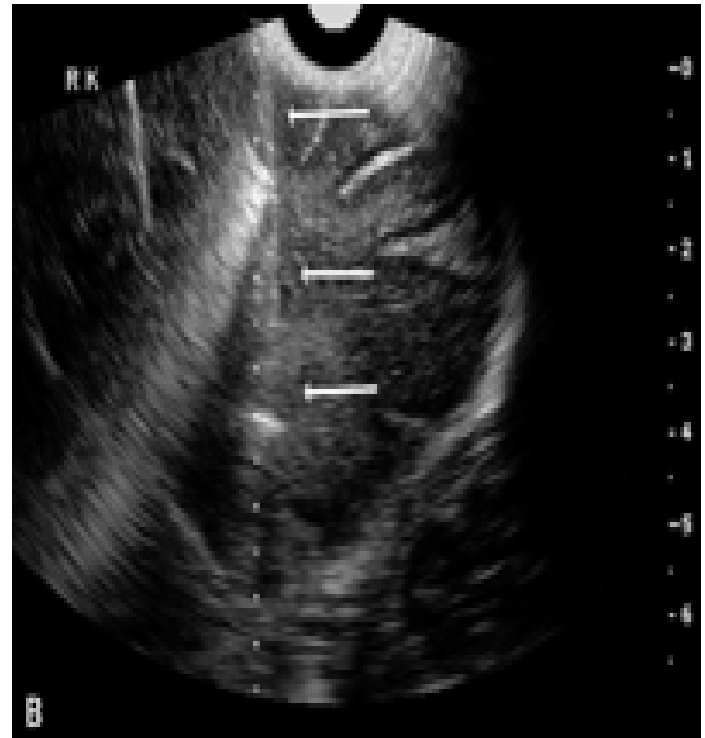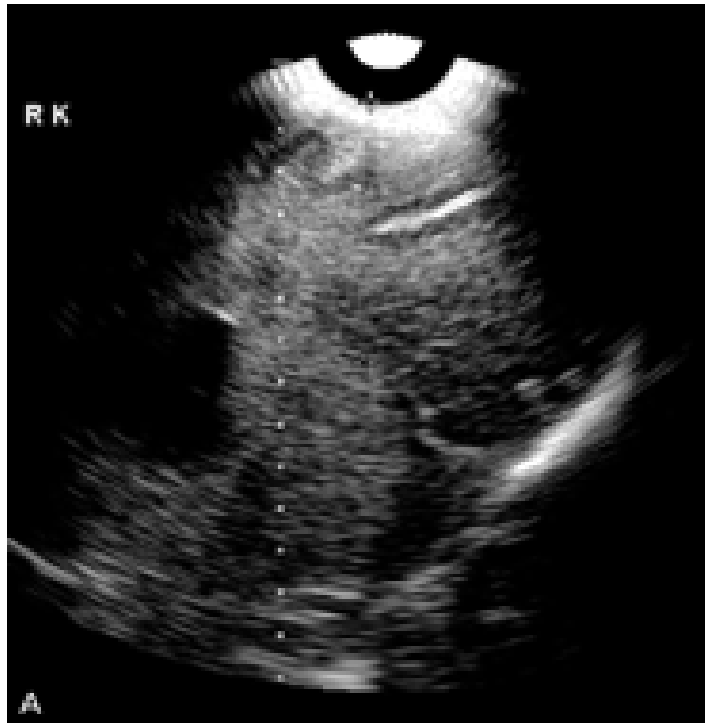Sonographically Guided Procedures in the Brain :

- To closely monitor the progression of cyst or abscess drainage in both supratentorial and infratentorial regions.
- To insert ventricular catheters.

INTRAOPERATIVE **ULTRASOUND**

- With a biopsy guide mounted on the transducer, direct a needle into the image plane along a predictable path.
- When a needle is inserted through the guiding device, its tip is continuously monitored as it approaches and enters the lesion to avoid damage to crucial adjacent structures.

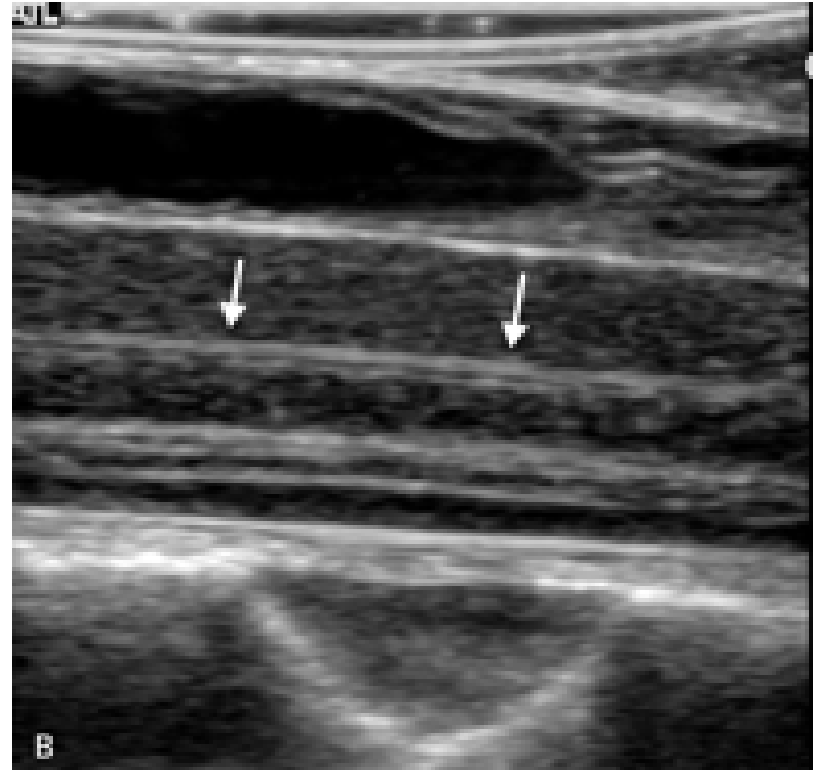
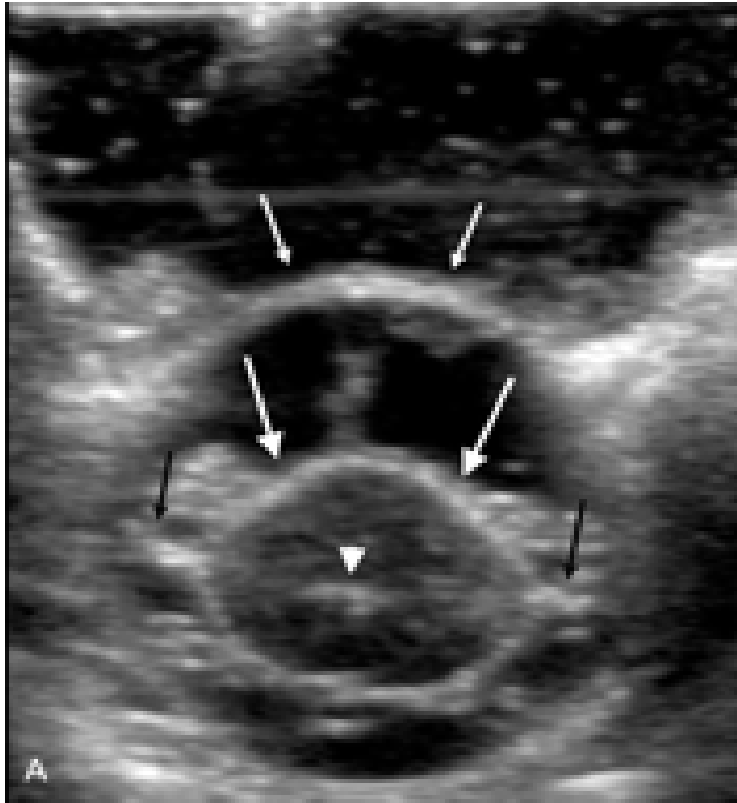
INTRAOPERATIVE ULTRASOUND



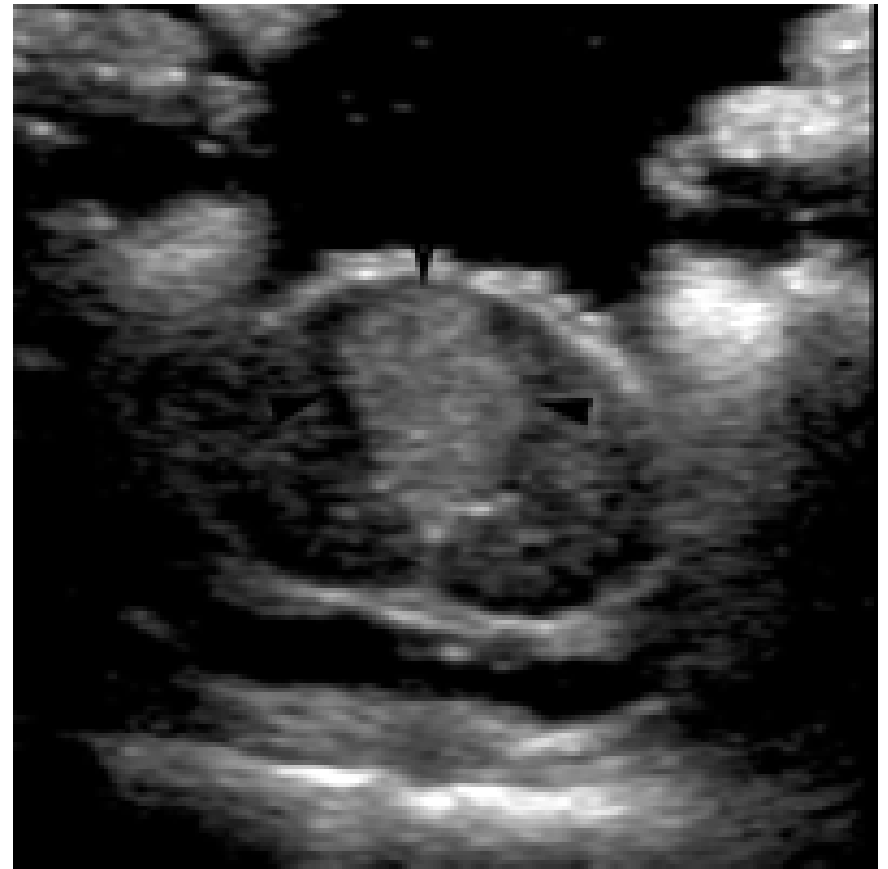
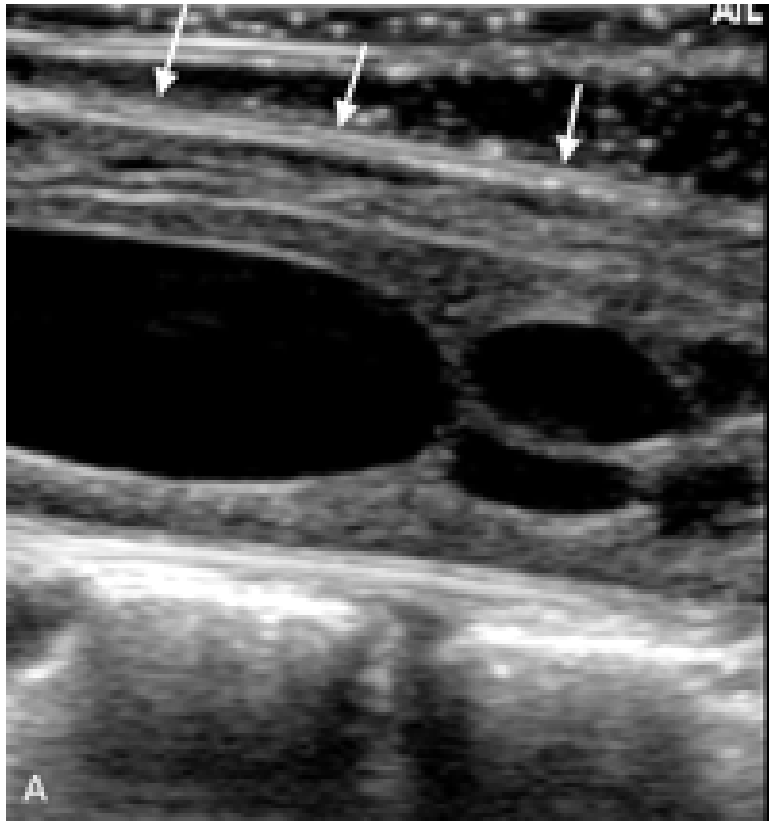INTRAOPERATIVE **ULTRASOUND**

- The best site for biopsy of solid lesions is the viable portion of a tumor. This is usually represented by the echogenic margin at the periphery of the mass.

INTRAOPERATIVE ULTRASOUND



INTRAOPERATIVE **ULTRASOUND**

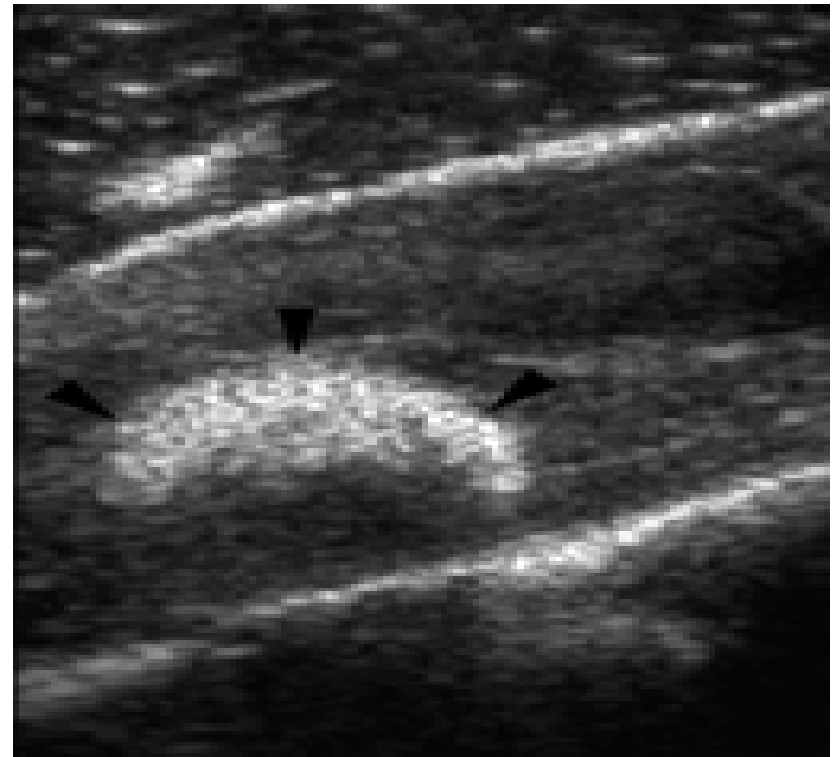
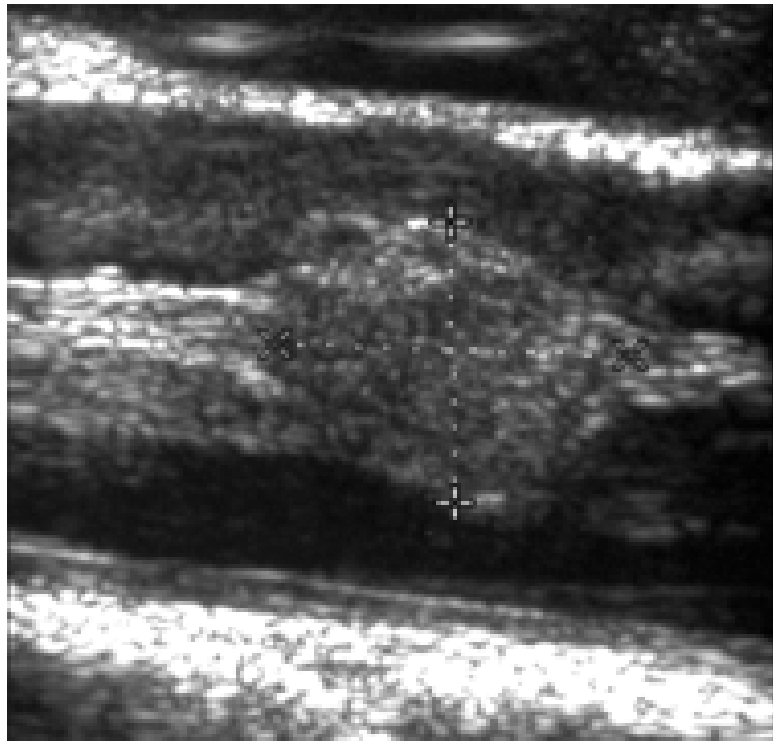


INTRAOPERATIVE **ULTRASOUND**

EXTRAMEDULLARY LESIONS

- Including neoplasms (such as meningiomas, neurofibromas), and non-neoplastic lesions that produce a mass effect (such as bony fragments, herniated disks, hematomas, cysts), are generally **hyper echoic relative to the adjacent spinal cord** and often displace or compress adjacent structures.

INTRAOPERATIVE ULTRASOUND



INTRAOPERATIVE **ULTRASOUND**

Sonographically Guided Procedures in the Spine

- For **syringohydromyelia**, during surgery sonography is used to limit unnecessary exploration, guide syrinx drainage via catheter placement, and assist in proper fenestration and drainage of loculated cysts.

INTRAOPERATIVE **ULTRASOUND**

Vessel Malformations

AV Angiomas

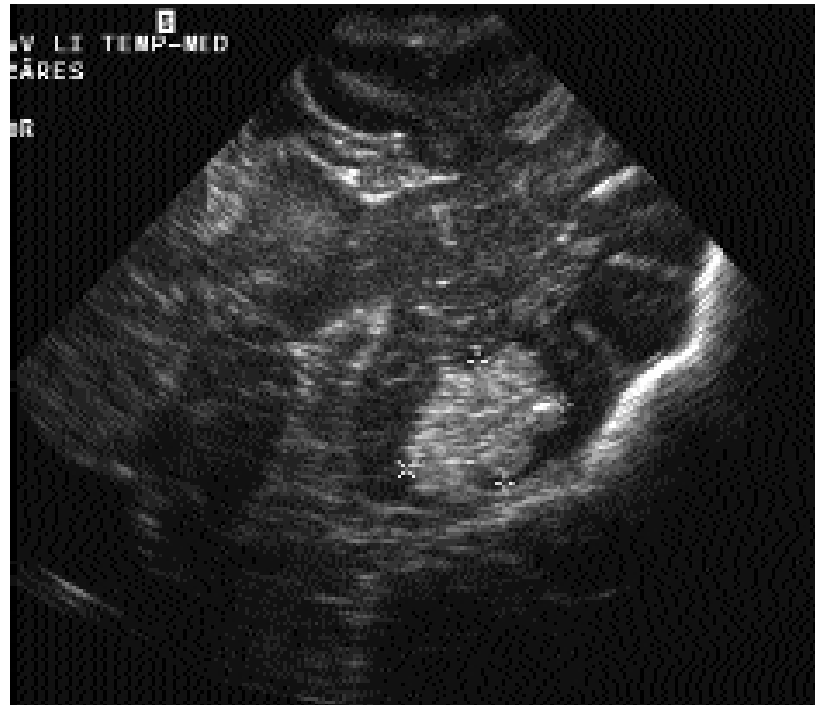- Helps in localizing the angioma nidus or any accompanying hematomas.
- Used to identify feeder or drainage vessels and for checking resections.
- The perfused part of the nidus appears as hypo echoic, while embolized parts appear hyper echoic.
- In the color-coded display, the nidus is shown by the blue and red vessels, which correspond to the vessel convolutions.
- Embolized parts does not show any color-code because there is no flow,

INTRAOPERATIVE **ULTRASOUND**

Cavernomas

- Cavernomas appear hyper echoic in the B-mode.
- The homogeneity depends on the number and freshness of the hemorrhages in the cavernoma and also on microcalcifications.
- It is significantly more difficult to distinguish them from the surrounding brain tissue when there is a high iron content in the surrounding brain tissue.

INTRAOPERATIVE ***ULTRASOUND***

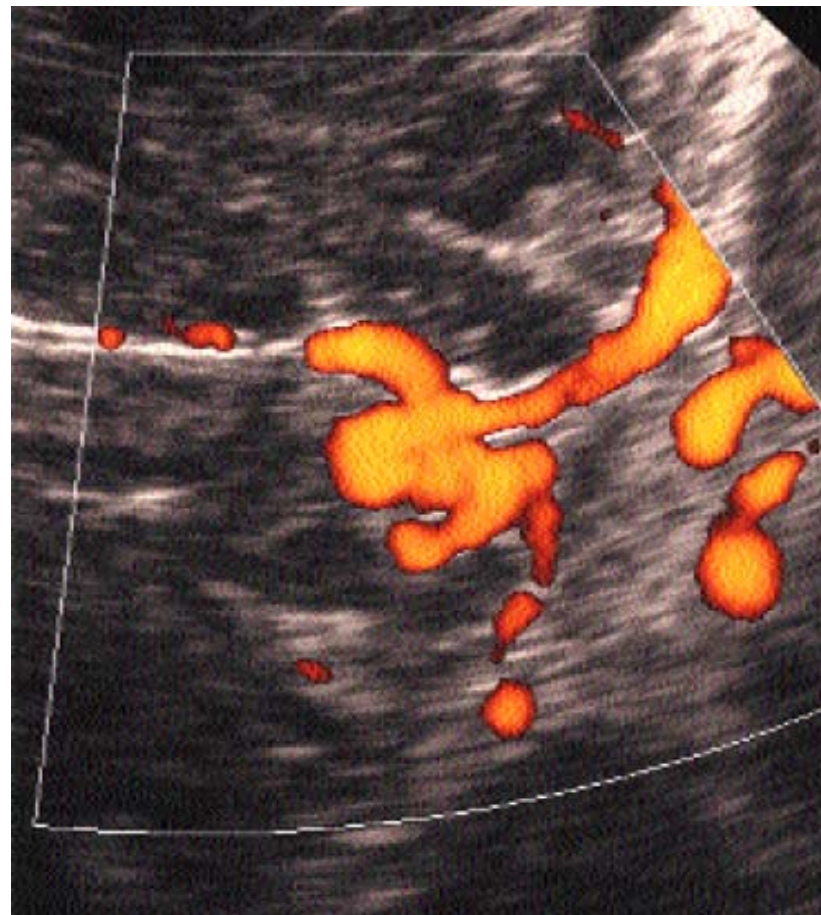
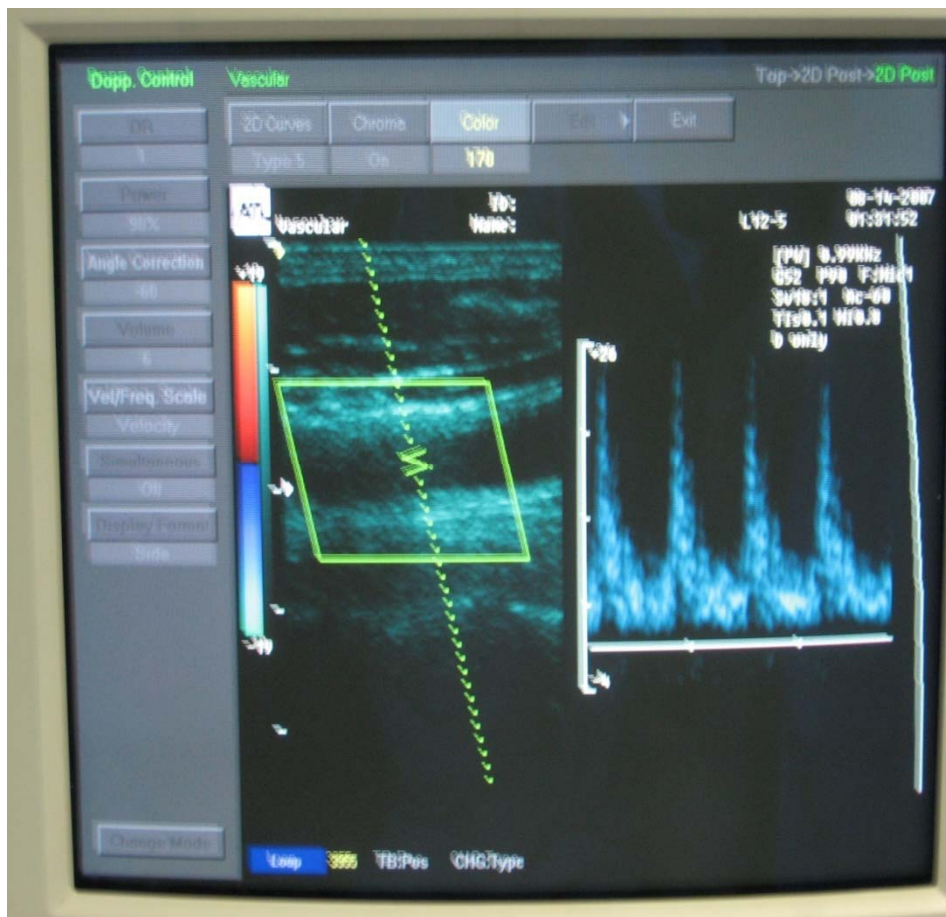


INTRAOPERATIVE **ULTRASOUND**

Cerebral Aneurysms

- Aneurysms with flow appear anechoic in the B-mode and thrombosed parts are echogenic.
- After the complete clipping, the aneurysm is echogenic because of the fresh thrombosis, and the color-coding and Doppler signal are no longer detectable.

INTRAOPERATIVE DOPPLER ULTRASOUND



INTRAOPERATIVE **ULTRASOUND**

LIMITATIONS

- Difficulty in distinguishing a tumor from normal tissue and lesion obscuration by chronic edema.
- Diminished role due to the widespread use of CT stereotaxis and real-time MRI fusion images.

INTRAOPERATIVE

ULTRASOUND

ADVANTAGES

- Safe & Non-invasive
- Real time imaging
- Rapid & effective way to **localize & Characterize** the disease of the Brain or spinal cord.
- Detects intraoperative dynamic **Brain shifts.**

3-D TRANSCRANIAL ULTRASOUND

- Provides a more comprehensive understanding of intracranial vessels & other intracranial structures.
- **Components:-**
 - 1) Ultrasound duplex system
 - 2) Transducer:- 2-MHz used for transtemporal insonation of intracranial arteries but higher freq.(3,or 4MHz) used for brain tissue esp. ipsilateral brain.
 - 3) Data acquisition system with workstation:- data for 3-D recons are obtained by using a magnetic sensor system.

3-D TRANSCRANIAL ULTRASOUND

PRINCIPLES

- The 3-D ultrasonic recon consists of 2-D ultrasonic images, the 3-D image quality depends on the quality of the acquired 2-D images.
- After acquisition, the raw data set is transformed in to a Cartesian coordinate system.

3-D TRANSCRANIAL ULTRASOUND

APPLICATIONS

- 1) Allow the assessment of intracranial hemodynamic changes & imaging of intracranial vessels.
- 2) Provides a more comprehensive understanding of brain structures such as the third & lateral ventricles, the thalamus, & the mesencephalon.

CONTRAST ENHANCED TRANSCRANIAL ULTRASONOGRAPHY

- ❖ The major limitation of TCU is that the temporal bone prevent insonation in 16-20% of patients older than 60 years of age.
- ❖ To overcome this drawback, echo contrast agents are used which increase the echogenicity of blood.
- ❖ **PRINCIPLE:-** Microbubbles in the injected fluid are the source of contrast effect & the effect is related to the different acoustic properties of air in comparison to the surrounding blood.


CONTRAST ENHANCED TRANSCRANIAL ULTRASONOGRAPHY

- ❖ The ability of the contrast agent to pass via the lung capillary bed increases the duration of the enhanced doppler signal e.g. Albumin (Albunex) or galactose palmitic acid preparations (Levovist) to coat & stabilize gas microbubbles.
- ❖ **USES:-**
 - 1) Patients with insufficient Doppler signals.
 - 2) For conclusive assessment of the intra-cranial cerebral arteries in patients with ischemic cerebrovascular disease.

STEREOTACTIC **LOCALIZATION :**

FRAME BASED

FRAMELESS




HISTORY OF STEREOTACTIC FRAMES

- In 1873, **Dittmar** designed a device for the medulla oblongata.
- **Zernov**, a Russian anatomist, developed the **Encephalometer**, an arc-based guiding device.
- **Robert Henry Clarke and Victory Horsley**, design an apparatus to study cerebellar function in the monkey.
- The **Spiegel and Wycis** design a plaster cap fitted to patient to which a head ring with electrode is attached.

TYPES OF STEREOTACTIC **FRAME SYSTEMS :**

- Translation / Orthogonal system;
- Arc system;
- Burr hole mounted;
- Interlocking arcs.



TYPES OF STEREOTACTIC FRAME SYSTEMS :



ORTHOGONAL FRAME

- **PRINCIPLE:** probes are inserted to a measured depth through coaxial holes in a grid that is mounted on a base plate orthogonal to the x or y axes.
- Orthogonal system was the basis for the Spiegel and Wycis apparatus (as well as the Horsley-Clarke device);

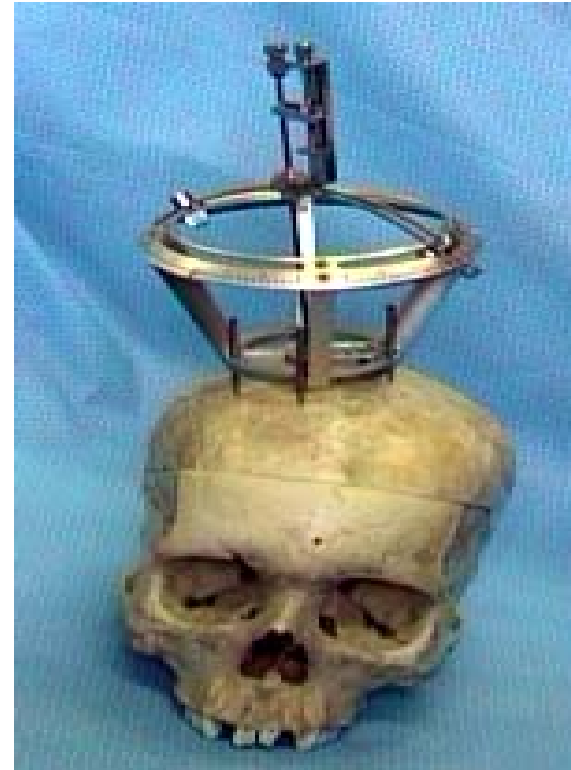
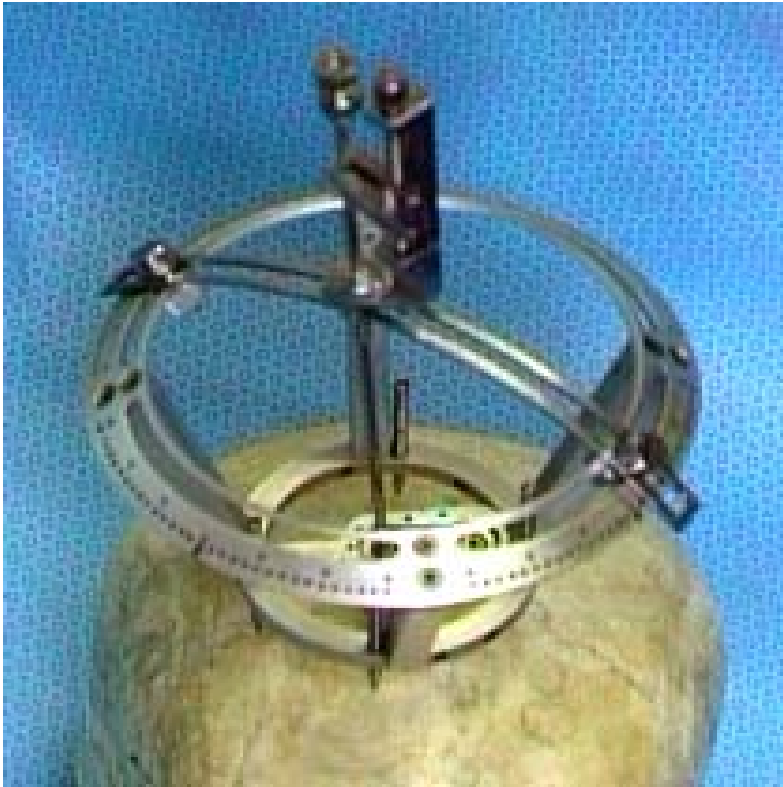HORSLEY - CLARKE ***STEREOTACTIC DEVICE***



Burr Hole-Mounted Systems

- Simple in design,
- Direct the probe to the target point from the fixed entry point at the burr hole.
- It provides two angular degrees of freedom and a depth adjustment.
- These instruments were usually threaded into the burr hole and ap and lateral radiographs obtained then surgeon judges the position of a target point on a contrast ventriculogram.

Burr Hole-Mounted Systems



Burr Hole-Mounted Systems

DISADVANTAGES

- Probe position in the depths of the brain was dependent on the angular settings of the burr hole-mounted apparatus.
- Limited range of possible intracranial target points with a fixed entry point.

USES

- For pallidotomy and thalamotomy, these devices were usually fixed into a coronal burr hole.


Arc-Quadrant Systems

- Originally described by Leksell in 1949.
- **PRINCIPLE** : probes are directed perpendicular to the tangent of an arc (which rotates about the vertical axis) and a quadrant (which rotates about the horizontal axis). The probe, directed to a depth equal to the radius of the sphere defined by the arc-quadrant, will always arrive at the center or focal point of that sphere.
- E.g. Leksell system, Todd-Wells apparatus ;
Riechert system

Leksell Stereotactic System

- Introduced by Professor Lars Leksell in 1949.
- The most widely used frame in the world.
- More Reliable, flexible, versatile and easy to use.
- The basic components are the cartesian coordinate frame and a semi-circular arc.

LEKSELL G BASE FRAME



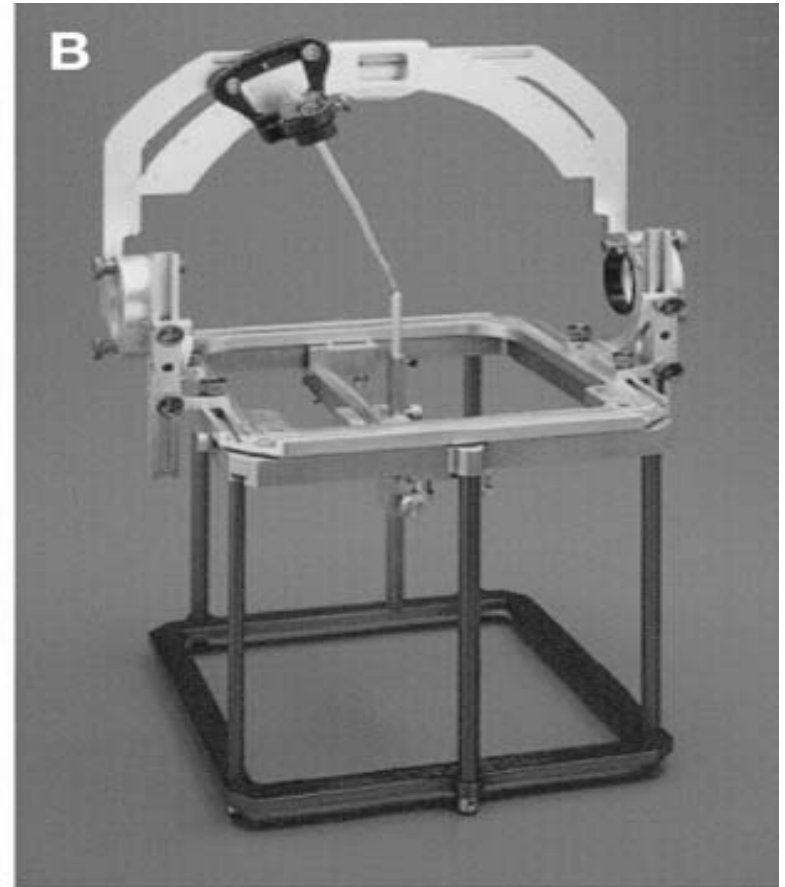

Leksell Stereotactic System

ADVANTAGES:

- The center-of-arc principle permits full flexibility in terms of access to all intracranial areas.
- It provides complete freedom of choice in trajectory and entry point selection.
- Posterior fossa, transphenoidal and lateral approaches are possible, in addition to all other approaches.

Arc-Phantom Systems :

- Introduced by Clarke in 1920.
- An aiming bow attaches to the head ring, which is fixed to the patient's skull, and can be transferred to a similar ring that contains a simulated target.
- Lateral targets, which are difficult to reach with arc-quadrant systems, may be attainable with the arc-phantom system.
- *E.g. **Brown-Roberts-Wells apparatus***
- **DISADVANTAGE**: complexity of adjusting the individual arcs to define a specific trajectory.



Cosman-Roberts-Wells (CRW) stereotactic system

A, MRI compatible head ring with attached Universal Compact Localizing Frame

B, Rectilinear pointer with CRW stereotactic frame calibrated to the target.

FRAME BASED STEREOTACTIC LOCALIZATION

DISADVANTAGES :

- Frame-based systems are bulky and uncomfortable for the patient
- Obstruct the operative field
- Limit the surgeon to targets along a straight-line trajectory
- None offers real-time feedback
- Obstruct access to airway for anesthesiologist.

Frameless Stereotactic systems

- Roberts and Friets introduced frameless stereotactic systems in the 1980s.
- **Theory behind stereotactic neurosurgery** –
 1. Three points define a volume in geometric space
 2. If the same three points can be defined on a patient and on an image of that patient, then the three-dimensional space of that patient and image are known and can be defined relative to each other

Frameless Stereotactic systems

- **Registration** is the process whereby the location of any point on or within the patient is defined on the image, and vice versa.
- These points may be anatomical landmarks or artificial markers.
 - Anatomical landmarks allow retrospective registration with existing images.
 - Artificial extrinsic markers do not allow this.

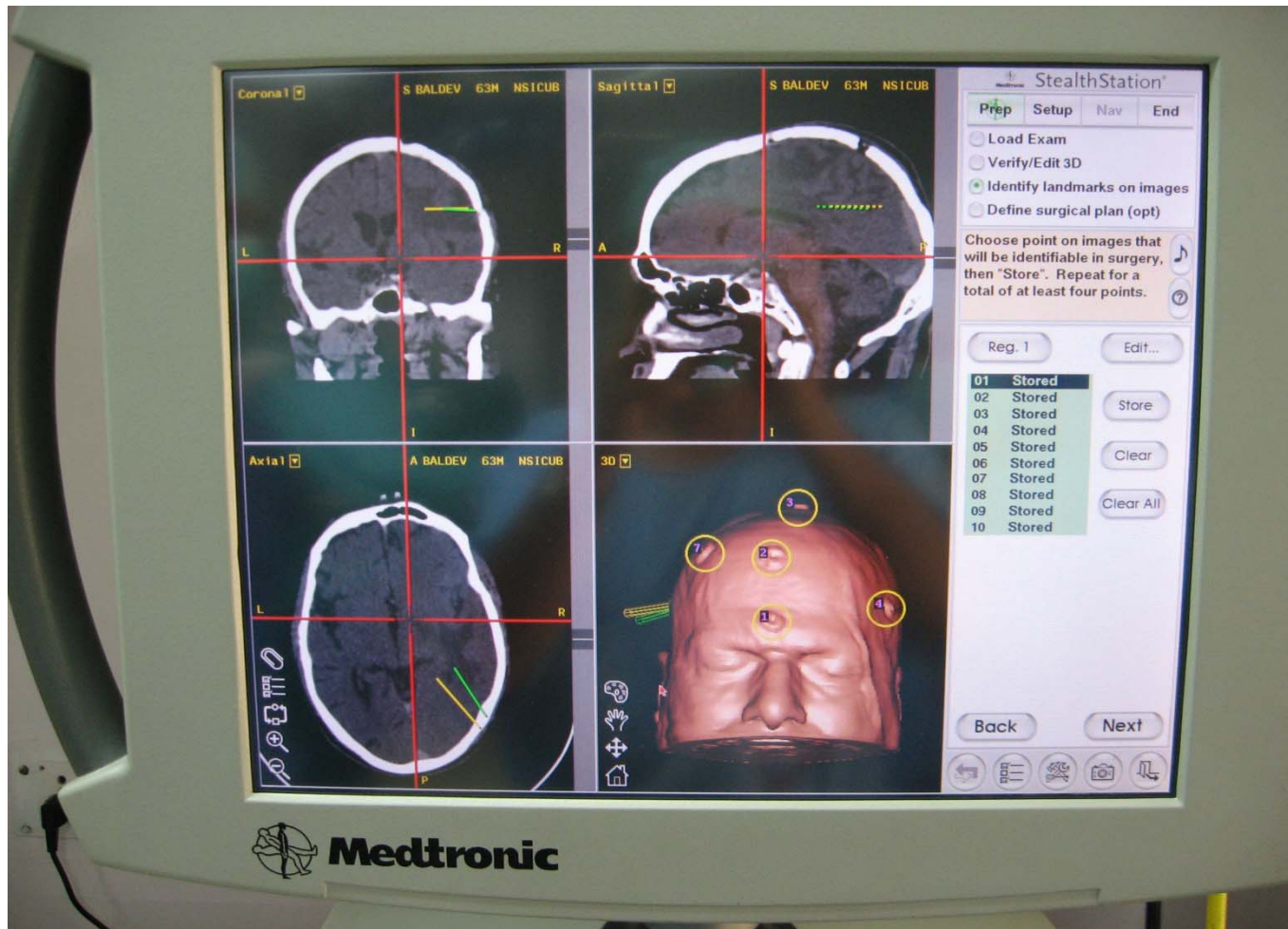
Frameless Stereotactic systems

- The choice of MRI or CT depends on the needs of the surgeon
 - when bony landmarks are main concern CT may be sufficient or ideal
 - For most intracranial applications MRI will be the modality of choice
- Scan data is transferred to the OR workstation by an **Ethernet** connection or by removable media as optical disks (“**sneakernet**”)

Frameless Stereotactic systems

- Landmarks for registration (scalp markers or anatomical points) are numbered on a 3-dimensional image reconstruction
- Registration is then done using at least four fiducials.
- At this point, navigation may be used to plan an incision and approach for craniotomy or stereotactic biopsy.

Frameless Stereotactic systems

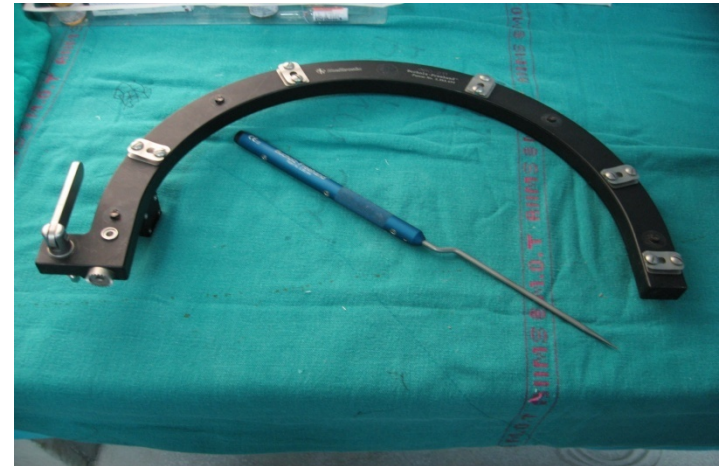
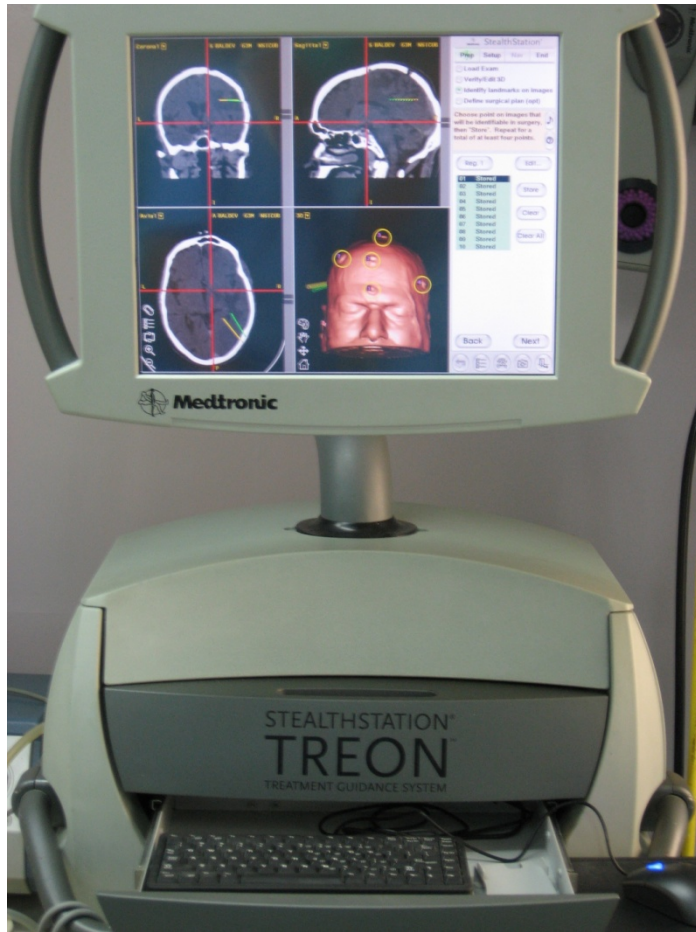
Frameless Stereotactic systems

Intraoperative location of a point in patient with image done with one of the devices :-

- The Neuronavigator (ISG Technologies, Toronto)
- OAS System (Radionics, Massachusetts).
- The PUMA Industrial Robot (Westinghouse Electric, Pennsylvania) is an active robotic arm system.
- **Stealth System (Bucholz; Surgical Navigation Technologies, Colorado)**
- ACUSTAR I (Codman Massachusetts) localize with infrared light-emitting diodes

Stealth System



Frameless Stereotactic systems

Brain shift

- In neuronavigation, data usually acquired from preoperative anatomical features considering head & its contents as a fixed structure.
- Brain shift occurs intra op due to CSF drainage, use of diuretics & tumor resection which makes an error in the accuracy of the preoperative data.
- Deeper structures, such as those at the skull base or along the falx shift less than superficial structures, improving the accuracy of stereotactic systems at those regions.

Frameless Stereotactic systems

STEPS TO MINIMISE TISSUE DISPLACEMENT

- Displacement is often greatest in the direction of gravity
- Minimizing diuretic use does not have an appreciable effect on displacement
- Cerebrospinal fluid shunting can cause shifts of tissues in unpredictable directions, so its use should be avoided until after the primary approach has been made
- Debulking of tumors in the “inside to outside” approach also yields significant tissue shifts; defining the outer margins of a tumor before proceeding with debulking may help to minimize this shift.

STEREOTACTIC SURGERY

AIIMS DATA
Jan 2003 – July 2007

- Frontal SOL 20
- Thalamic sol 17
- Parietal SOL 7
- Basal ganglia SOL 6
- CNS lymphoma 5
- Epilepsy Surgery 4
- Temporal glioma 4
- Brain abcess 3
- Brainstem cavernoma 3

STEREOTACTIC SURGERY

- Corpus callosum glioma 3
- Insular glioma 3
- CNS metastasis 2
- Gene therapy 2
- AVM 1
- Pituitary macroadenoma 1
- Pontine cavernoma 1
- Residual parafalcine meningioma 1
- Tectal glioma 1
- C3-4 NF 1

INTRAOPERATIVE / MOBILE CT

SCAN :

- Gantry translation rather than by translation of the patient table which permits the scan intraoperatively.
- The scanner is equipped with wheels, runs on wall outlets (120V, 20A) in combination with batteries, and has a translating gantry.
- An operating table adaptor was built for use with a radiolucent cranial fixation device.

INTRAOPERATIVE / MOBILE CT

SCAN :

- Prior to draping, the fit of the head into the gantry is confirmed with a metal loop with same inner diameter as the CT gantry.
- Intraoperatively patient is positioned in a radiolucent headframe,
- A clear sterile bag is placed over the sterile field, &
- The gantry is positioned about the head, and the CT scan is obtained.

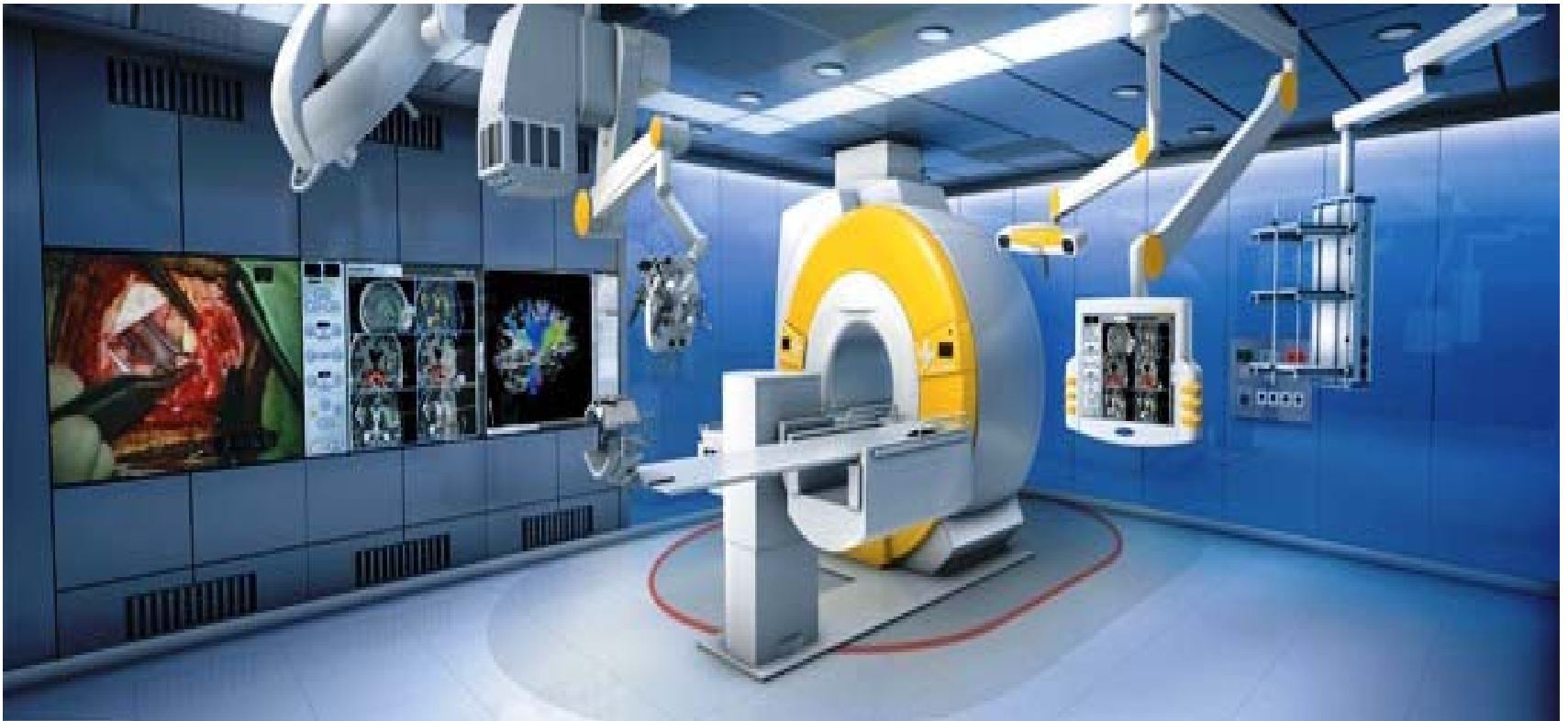INTRAOPERATIVE / MOBILE CT

SCAN :

ADVANTAGES :

- Make intraoperative CT available to a maximum number of cases.
- Permit intraoperative CT while requiring minimal preoperative planning.
- Require minimal or no change in existing surgical protocols, routines or instruments.
- Allow intraoperative CT on-demand at any point in the case.

INTRAOPERATIVE MRI :



INTRAOPERATIVE MRI :

- Mobile, 1.5 Tesla MRI system
- Also k /a “BRAINSUITE”
- The use of the first intra-operative MRI started in 1995 with the so-called 'double doughnut design' dedicated to use in operating room.
- BrainSUITE is a neurosurgical OR that fully integrates all the surgical and diagnostic tools, including iMRI.
- M. D. Anderson's BrainSUITE is the world's first fully integrated open MRI system with a 70-centimeter magnet, which can accommodate even large or obese patients.

INTRAOPERATIVE MRI :

- In New Delhi, MAX Hospital, has a scanner of SIEMENS (Siemens AG Medical Solutions, Erlangen, Germany) with a superconductive active shielded magnet with a length of 160cm & an inner bore diameter of 60cm.

INTRAOPERATIVE MRI :

PROCEDURE :

- Patients head fixed on an MRI compatible 4-point head fixation device.
- Two head coils to perform MRI, one kept sterilized by formalin tablets for imaging during surgery.
- First MRI done & then registration of images in the navigation system performed taking skull fixation points as landmarks.
- Image fusion,
- Sterile tracking probe fixed to the head fixation device to perform surgery.

INTRAOPERATIVE MRI :

CHANGES IN THE OT ROOM :

- The entire OR has to be Radiofrequency shielded from superconducting magnets.
- No metal instrument on opt. table during imaging.
- Tubing's , IV or IA lines should be longer than normal (6m) to allow access for MR gantry.

INTRAOPERATIVE MRI :

BrainSUITE are particularly useful for : -

- Primary brain tumors (Gliomas)
- Metastases to the brain
- Meningiomas
- Pituitary tumors
- Craniopharyngioma

INTRAOPERATIVE MRI :

ADVANTAGES :

- Accurate localization and lesion targeting,
- To assess the resection volumes,
- Enable corrections for brain shift,
- Perform further tumor resection at the same sitting and help preserve eloquent cortical areas.
- Detect acute complications such as hemorrhage and ischemia.

INTRAOPERATIVE MRI :

DISADVANTAGES :

- Integrated head fixation device / MRI coil which restricts all type of pt. positioning, making it impossible for Occipital & Posterior fossa lesions.
- The table can not be broken & varying positions like flexing the head, extension or sitting, are not possible.
- Functional MRI's have to be done in routine MRI which adds to the cost of the procedure.
- A long standing fatiguing procedure.

INTRAOPERATIVE **NEUROPHYSIOLOGY:**

- **GOALS :**
 1. To prevent intraoperatively induced injury.
 2. To document the exact moment when the injury occurred.
- Includes :- Mapping & Monitoring.

CORTICAL MAPPING :

- A technique to identify anatomically indistinct neural structures by their neurophysiologic function to prevent injuring the critical structures.
- PROCEDURES :
 - ❖ Mapping of sensory motor cortex with phase reversal median N. somatosensory evoked potentials (SEPs)– indirectly identify the Central Sulcus.

To confirm this, Direct cortical stimulation is needed to localize the motor cortex.
 - ❖ Mapping of Cranial nerve motor nuclei on the surgically exposed floor of the fourth ventricle.

MAPPING OF MOTOR NUCLEI OF CRANIAL NERVES ON THE FLOOR OF THE FOURTH VENTRICLE

- Handheld Monopolar stimulating probe used for electrical stimulation of motor nuclei.
- Compound muscle action potentials in muscles innervated by cranial motor N.
- Single stimulus of 0.2msec duration at a repetitive rate of 2Hz with intensity of 1mA.

MAPPING OF MOTOR NUCLEI OF CRANIAL NERVES ON THE FLOOR OF THE FOURTH VENTRICLE

LIMITATIONS :

1. In c/o VII N., it can not detect injury to the supranuclear tracts originating in motor cortex.
2. In c/o IX N. Mapping, it assess only the functional integrity of the efferent arc of the swallowing reflex with no information on the integrity of afferent pathways or afferent / efferent connections in the brain stem.

INTRAOPERATIVE NCV / EMG :

- Principle :
distal latency, SNAP, & CMAP.
- Applications :
 1. Facial nerve study in acoustic neuroma as well as for Hemifacial spasm by monitoring neurotonic discharges during surgery.
 2. Peripheral nerve study: to ensure the continuity or localization of a conduction block.
 3. Needle recording from the anal sphincter in Tethered cord surgery to avoid transecting the roots
 4. For selective dorsal rhizotomy to selectively sectioned the root fascicles.

New intraoperative tumor delineation methods (Future perspective):

- Dagherhian *et al.* (1994) developed a device for detecting **tumor labeled** intraoperatively *with **positron or electron-emitting isotopes.***
- The detector is sensitive only to short-range beta radiation and allows the localization of small lesions.
- The ability of the beta probe to successfully localize tumor intraoperatively is based on high-affinity, specific ligands that bind to tumor cells and have little or no binding to normal brain tissue.

New intraoperative tumor delineation methods (Future perspective):

- ❖ Haglund *et al.* (1996) performed for the first time **enhanced optical imaging** during surgery for the resection of cerebral gliomas using an **intravenous dye**.
- ❖ Possibly due to blood-brain barrier breakdown marginal sites of residual tumor showed a different dye uptake pattern with time demonstrated by high-resolution CCD cameras and computer-imaging processing.
- ❖ The method was most helpful for the resection of high-grade astrocytomas but most difficult for the distinction between tumor and nontumor in the low-grade gliomas.

“ Thank U ”
